

Cervical Disc & Ozononeucleolysis

Dr. Umair Rashid Chaudhry
Lahore-Pakistan

PERCUTANEOUS THERAPY OF DISC LESIONS

- Minimal invasive techniques have developed as alternative treatment to surgical intervention

TECHNIQUES

- Chemodiscolysis with chymopapain
- **Chemodiscolysis with O_2-O_3**
- Percutaneous laser disc decompression (PLDD)
- Intradiscal electrothermal therapy (IDET)
- Percutaneous coablation nucleoplasty
- Others, Jellified ethyl alcohol (discogel) etc.

MOA

- N.P.

- Fibrous Annulus

INCLUSION CRITERIA

- Brachialgia not responding to conservative treatment
- MRI / Myelo-CT / Myelography ++

EXCLUSION CRITERIA

- Pregnancy
- Motor loss
- G6PD deficiency

- Low Cost
- Low Complicate rate
- Easily feasibility
- Short hospital stay
- Not exclude the possibility of surgery

- CT guided

- **Angio Fluoro scopy guided**

OZONUCLEOLYSIS

- Intradiscal
- Paravertabral

LESIONS

- Single Disc prolapse
- Multiple Disc prolapse

SESSIONS:

- SINGLE
- MULTIPLE

EFFECTS

- Direct
 - Shrinkage

- Indirect
 - Analgesic
 - Anti inflammatory
 - Oxygenation

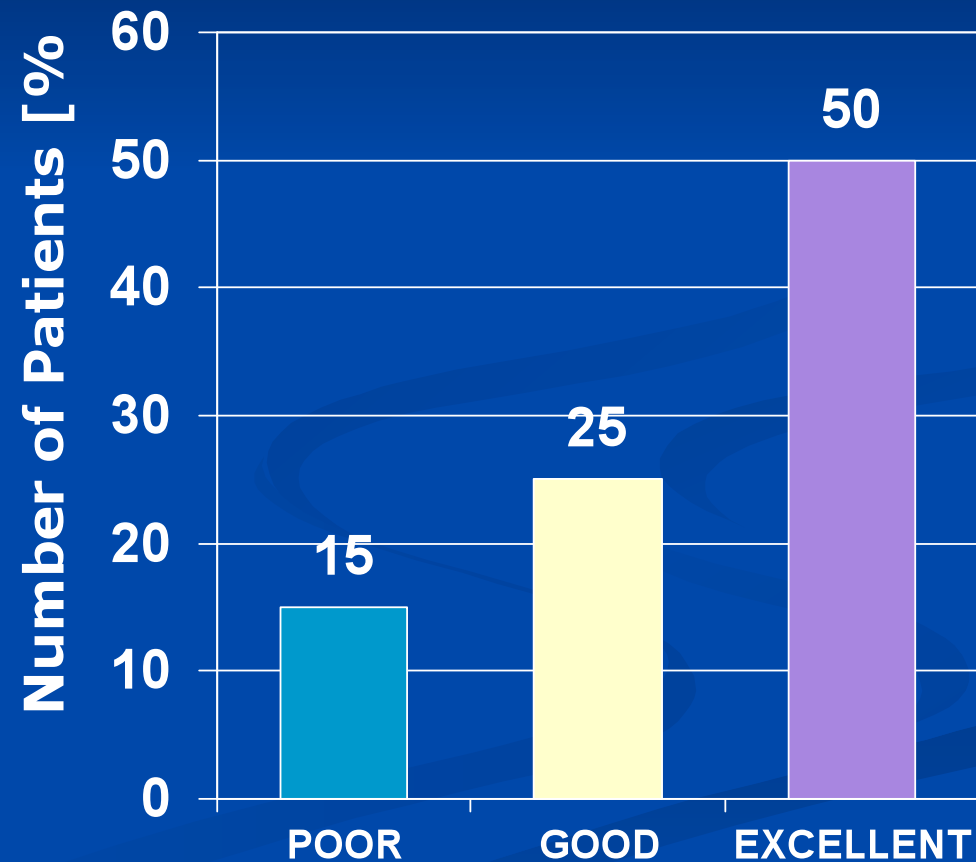
RESULTS

- A satisfactory therapeutic outcome was obtained. 50% of the patients showed complete recovery with resolution of symptoms.
- 25% of the patients complained of occasional episodic neck pain and arms with no limitation of occupational activity.
- 15% of cases showed insufficient improvement.
- 5% of cases had insufficient improvement and went for surgery.
- 10% of cases never turned up after the first visit.

RESULTS

**TOTAL
NUMBER OF
PATIENTS
TREATED: 4000**

**PERIOD:
June 2005 –
July 2016**

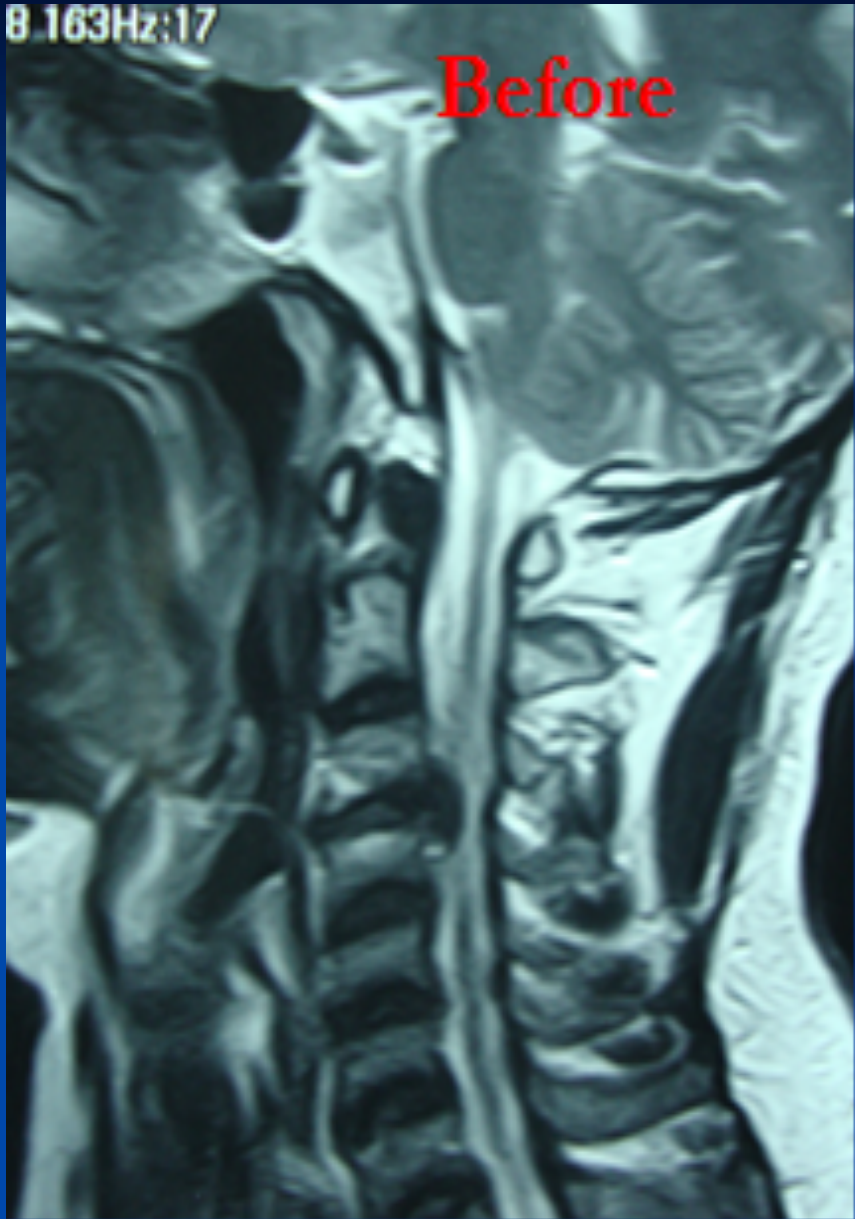


CONCLUSION

Intradiscal and periganglionic injection of Ozone for herniated cervical disc has revolutionized percutaneous approach to nerve root diseases making it safer, cheaper and easier to repeat than treatments currently in use.

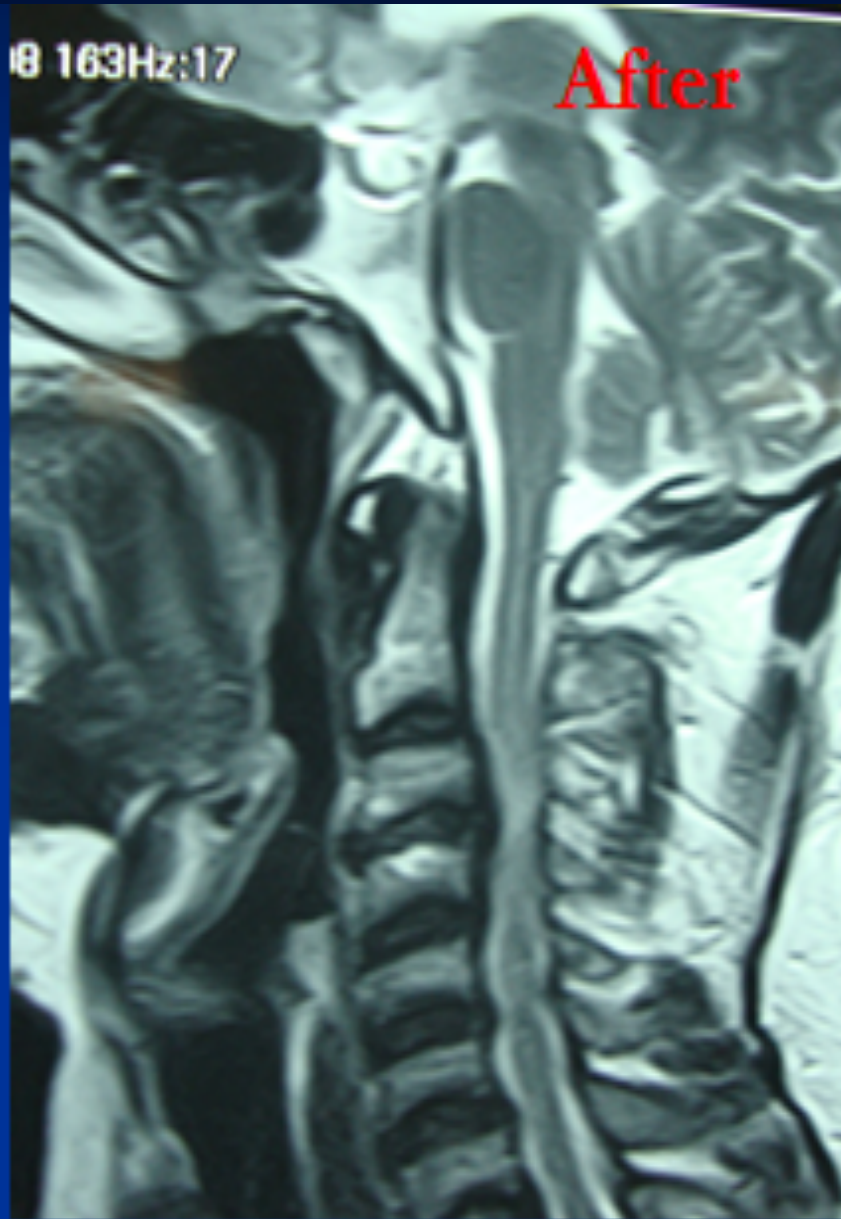
8 163Hz:17

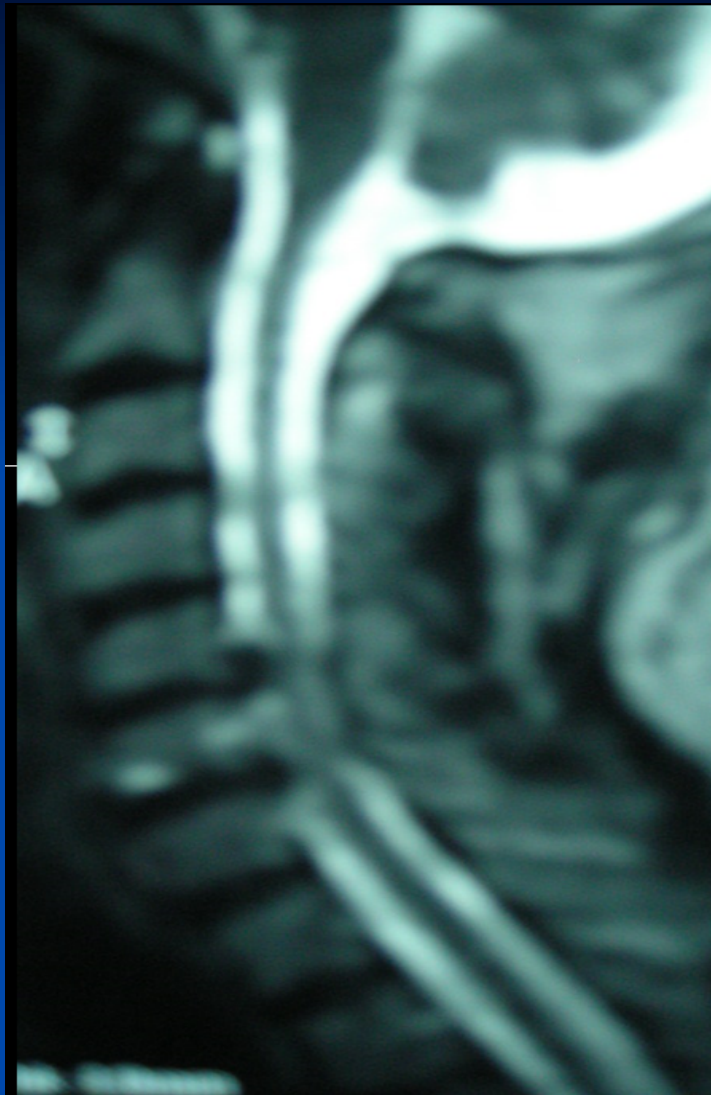
Before



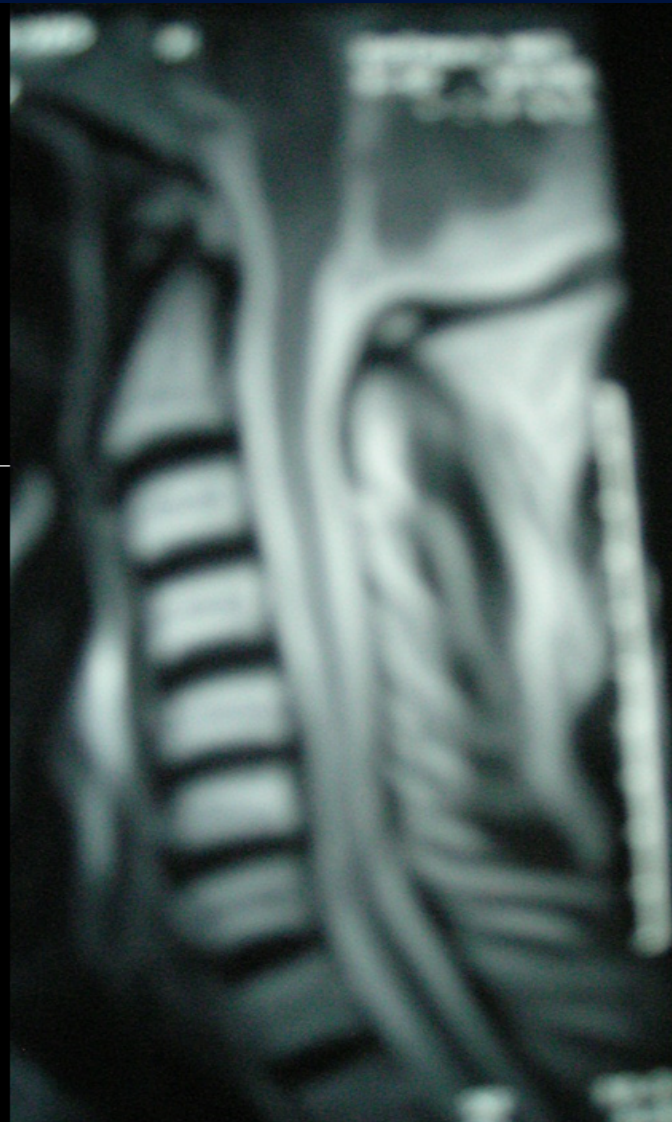8 163Hz:17

After

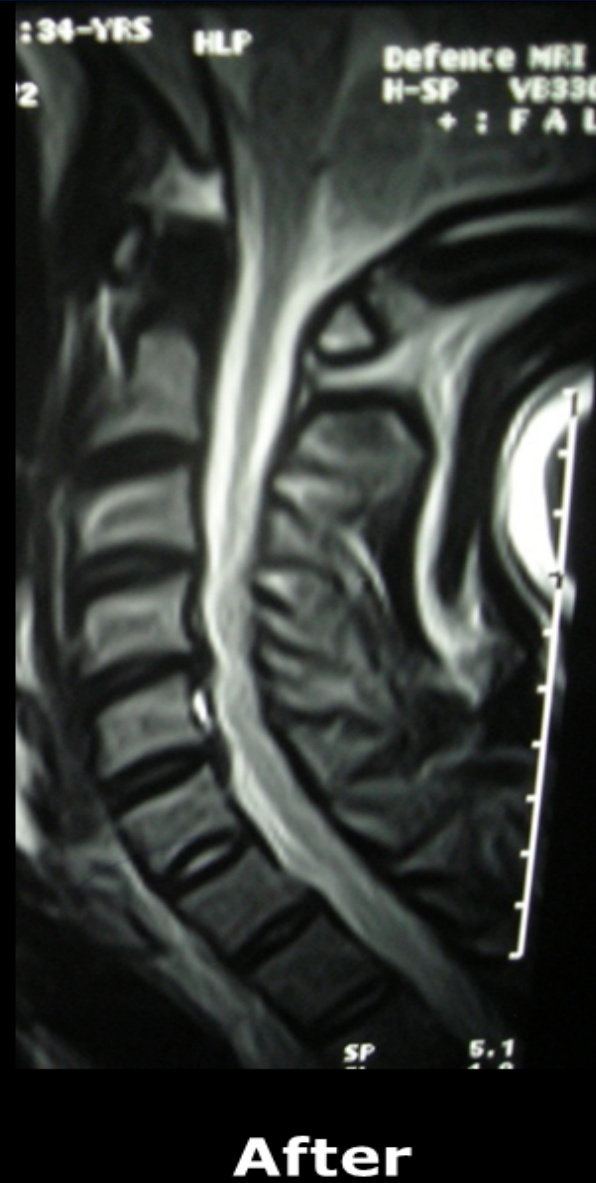
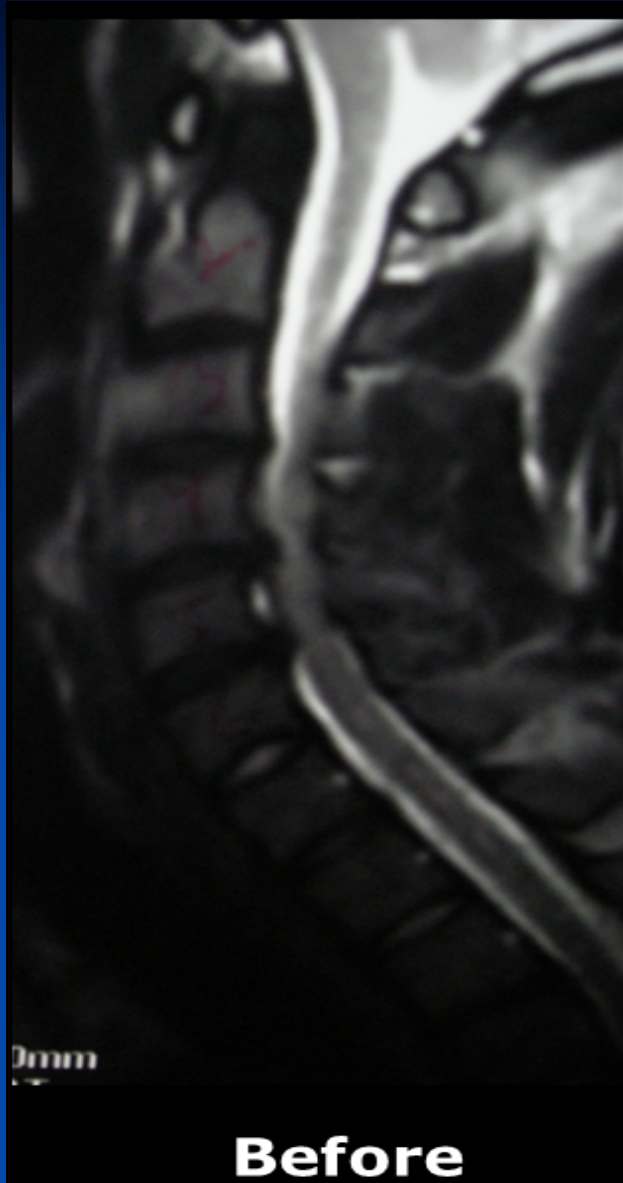


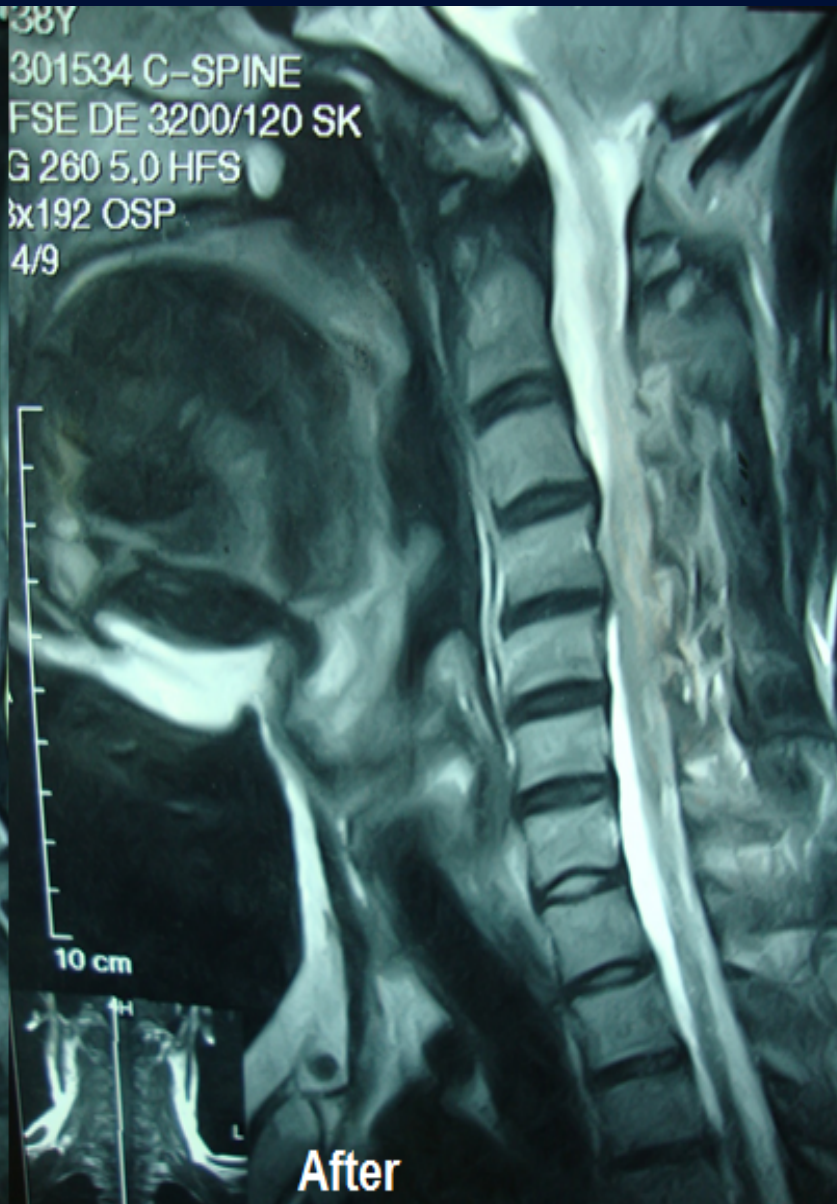
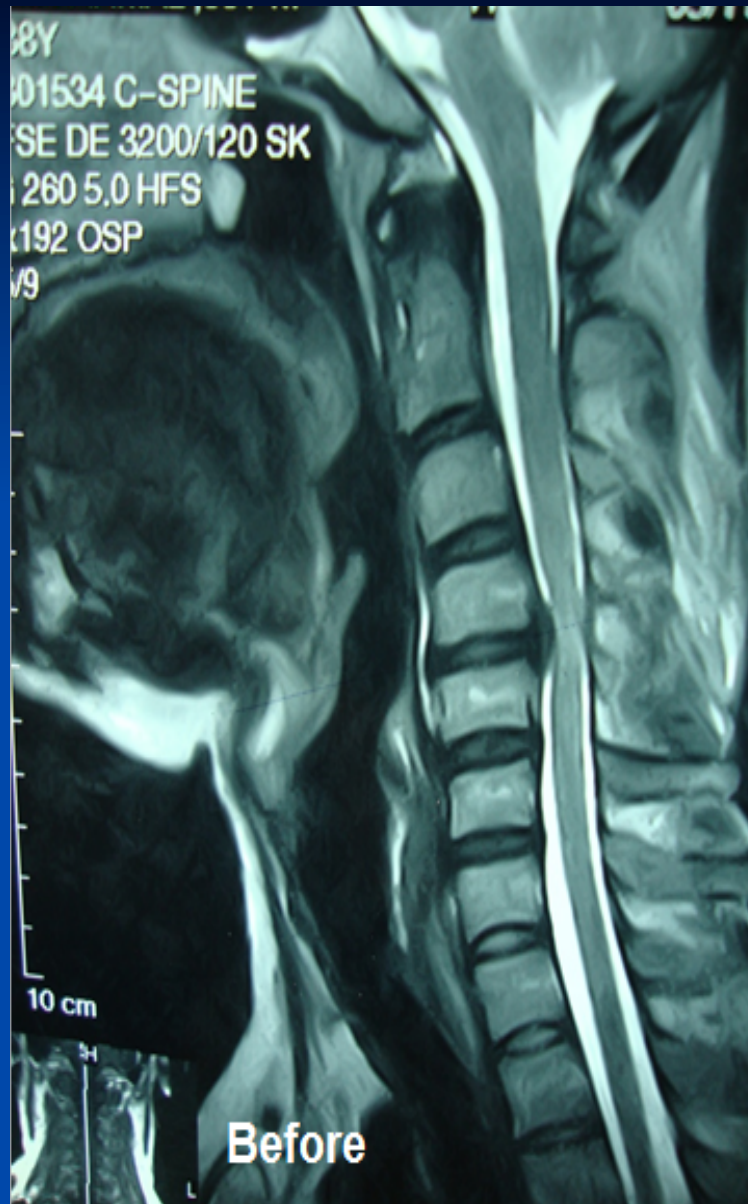

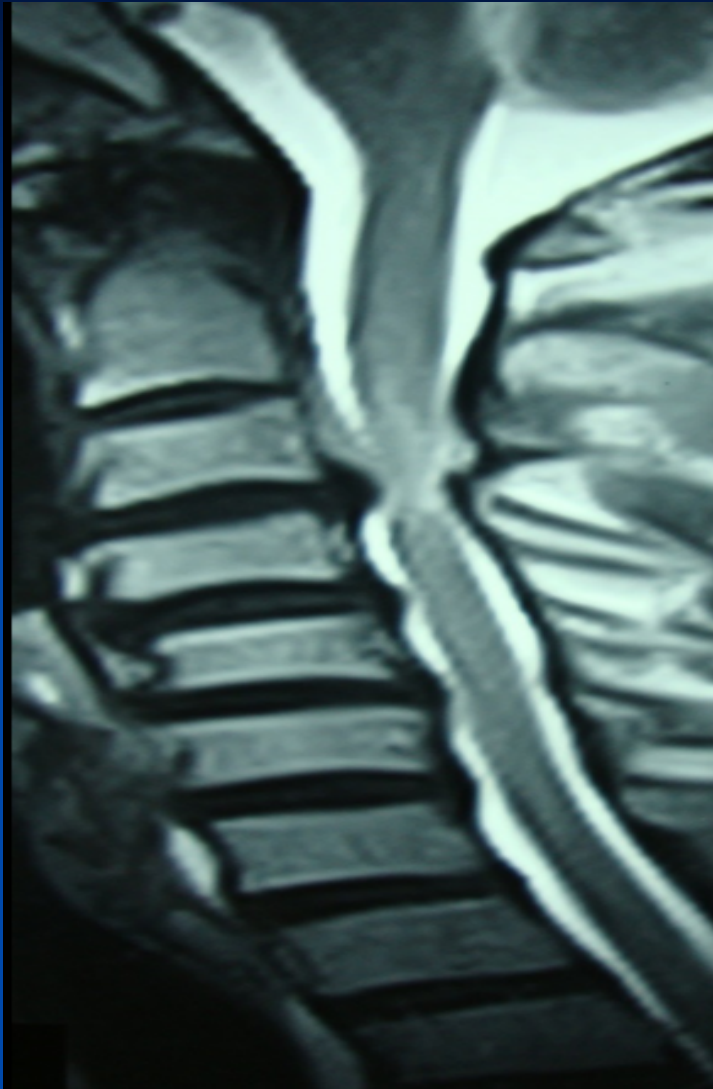
Before



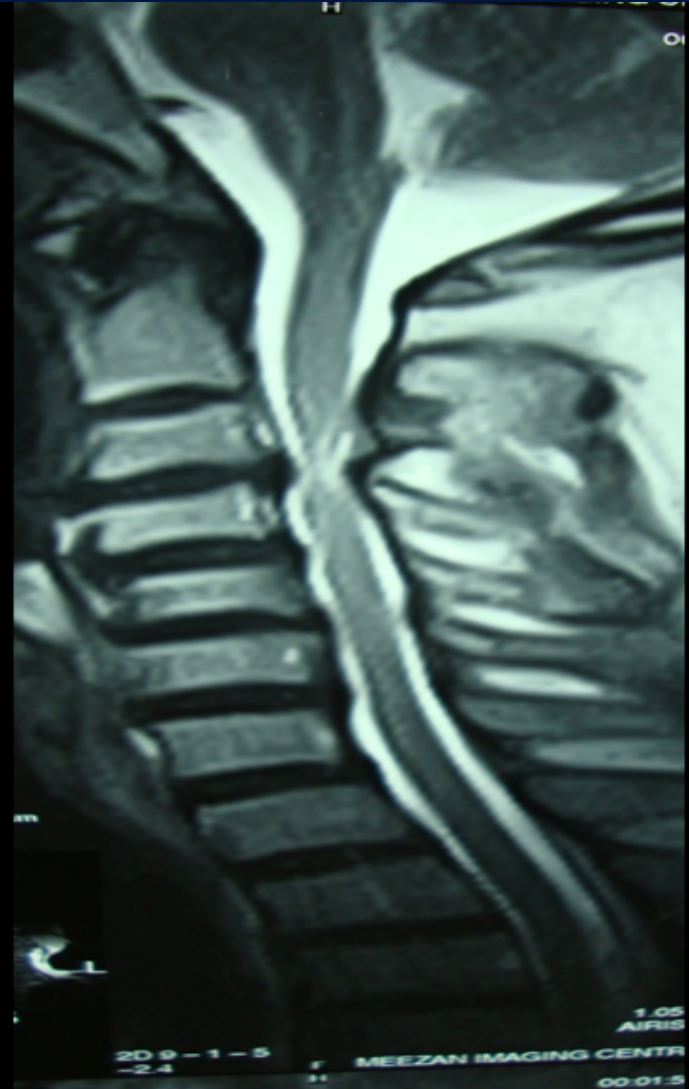
After







**Before
C3-4**



After

THANK YOU